

Magnetic Resonance Imaging (MRI) of Sexual Intercourse: Second Experience in Missionary Position and Initial Experience in Posterior Position

A. FAIX

Department of Urology, CMC Beau Soleil, Montpellier, France

J. F. LAPRAY

Department of Radiology, CMC Beau Soleil, Montpellier, France

O. CALLEDE

Department of Radiology, CMC Beau Soleil, Montpellier, France

A. MAUBON

Department of Radiology, CMC Beau Soleil, Montpellier, France

K. LANFREY

Department of Urology, CMC Beau Soleil, Montpellier, France

Our objective was to confirm that it is feasible to take images of the male and female genitals during coitus and to compare this present study with previous theories and recent radiological studies of the anatomy during sexual intercourse. Magnetic resonance imaging was used to study the anatomy of the male and female genitals during coitus. Three experiments were performed with one couple in two positions and after male ejaculation. The images obtained confirmed that during intercourse in the missionary position, the penis reaches the anterior fornix with preferential contact of the anterior vaginal wall. The posterior bladder wall was pushed forward and upward and the uterus was pushed upward and backward. The images obtained from the rear-entry position showed for the first time that the penis seems to reach the posterior fornix with preferential contact of the posterior vaginal wall. In this position, the bladder and uterus were pushed forward. A different preferential contact of the penis with the female genitals was observed with each position. These images could contribute to a better understanding of the anatomy of sexual intercourse.

Leonardo da Vinci depicted “the copulation” in 1493 (Clark & Pedretti, 1968), after which, we had to wait until 1949 for the first study of the interaction of male and female human genitals during coitus (Dickinson, 1949; Figure 1). A glass test tube, as big as an erect penis, was inserted into the vaginas of the female subjects, who were sexually aroused by clitoral stimulation. This guided Dickinson in the formulation of his anatomical suppositions. As you can see from Figure 1, in the missionary position, the penis reaches the posterior fornix. In the 1960s, Masters and Johnson (1966) carried out their assessments with an artificial penis that could mechanically imitate natural coitus and allow direct observation. The most remarkable observation regarding the anatomical vaginal changes was the backward and upward movements of the anterior vaginal wall called “vaginal tenting.” In the 1990s, Zwang (1990) imagined, in a theoretical diagram, that the penis preferentially reaches the posterior fornix in any coital position (see Figure 2). In 1992, Riley and Riley published an ultrasound study of copulation that investigated the behavior of a new intravaginal barrier contraceptive device during the penile thrusting in normal human coitus. Although the images were relatively poor quality and were unavailable for viewing, the conclusions were interesting. In 9 out of 10 couples, there was an indentation and stretching of the anterior wall of the vagina and no direct impact on the posterior wall in any coital position. However, in 2 out of 9 couples in rear-entry position, there was an impact on the cervix. Schultz, VanAndel, Sabelis, and Mooyart (1999) carried out a study by MRI on 8 couples and 3 single women. In 3 out of 4 couples with complete penetration, there was a preferential contact of the penis with the anterior fornix and vagina wall. In the fourth case, the uterus seems to be retroverted, however, we do not see a magnetic resonance imaging (MRI) image of the female pelvis prior to penetration. The last part of this study involved observing clitoral stimulation in 3 single females. There was a lengthening of the vagina but no increase in the uterine volume. Faix

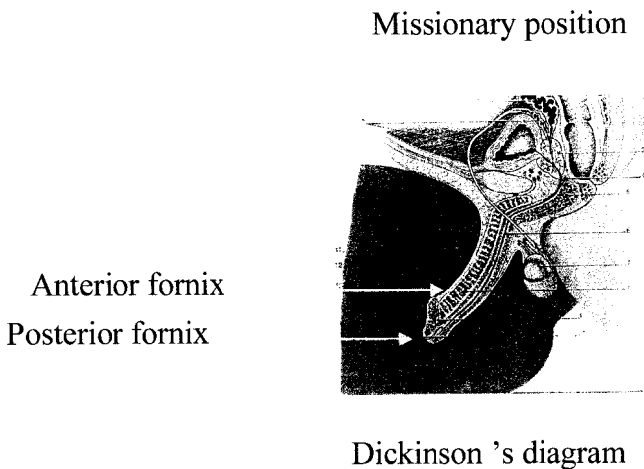


FIGURE 1. Dickinson's (1949) diagram

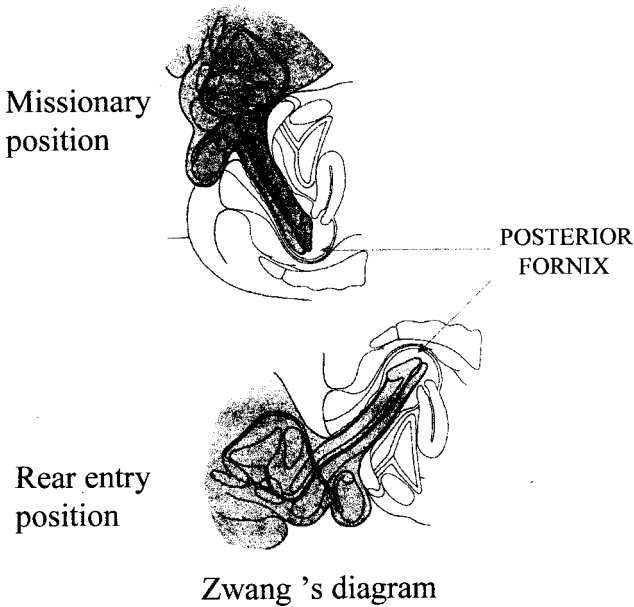


FIGURE 2. Zwang (1990) diagram

(2001) also carried out an MRI study in which he showed that in the missionary position, there was preferential contact of the penis with the anterior fornix and the anterior wall of the vagina. As can be seen from these theoretical and radiological studies, there were contradictions concerning the preferential impact point of the penis, according to the position. Except for the ultrasound study by Riley & Riley (1992), there was no live study of coitus in the two natural positions (missionary or rear entry). MRI had already been used as a diagnostic tool to study erectile impotence. The obvious advantage of MRI is the production of safe images with precise anatomical details that are clearer than those obtained from ultrasonography. The aim of the current study was to confirm the first MRI study of coitus and the observe the anatomical differences between the two different positions, using the same couple.

METHODS

The couple have a normal private life and were recruited by personal invitation. They both signed an informed-consent form. This project was approved by the ethical committee. The male measures 180 cm and weighs 80 kg. His erection is 16 cm long and looks normal (no congenital curvature). The female measures 167 cm and weighs 52 kg. Her gynecological examination is normal and she is parous (one normal delivery in 1995). They have a normal sexual life, with sexual intercourse occurring usually 4 times a week.

They have no erectile or dysorgasmic problems. The couple were guaranteed confidentiality, privacy, and anonymity.

The details of the MRI machine were:

- General Electric 1 Tesla
- Single shot fast spin Echo (SSFSE)
- Static T2 weighted sagittal sequences on the midline
- TE (time echo) = 18
- TR (time repetition) = 6000 ms
- Matrix = 256–192

The couple were invited to come for a scan at night, when the equipment was available. The volunteers were shown the equipment in the two rooms. The experimental procedure was explained and the investigators left the imaging room. The research team sat behind the scanning console and screen. An improvised curtain covered the window between the two rooms; the intercom was the only means of communication. The internal diameter of the tube was 60 cm, which, once in position, leaves a space of only 3 cm between the back of the male and the top of the tube.

There were four sessions. The first session, without penetration, was to initialize the machine parameters. The female was asked to ensure that her urinary bladder was as empty as possible. In the second session, the couple began sexual intercourse outside the MRI tube (45 min after the male had taken 50 mg of Viagra). They then lay in position on the ramp: The female lying on her back with her legs slightly open and the male lying on top of her (missionary position). The team checked the position on the midline through the different slices to guide the couple during coitus. In the third session, the couple changed positions, with the female lying on her abdomen, bottom slightly turned upward, and the male on top on her (rear-entry position). In the fourth and last session, the couple again performed the missionary position to attempt to reach orgasm. Only the male succeeded. Unfortunately, because of the increased movement within the tube, the images of the male ejaculation were not available; there were only images available immediately after ejaculation. During the three sessions with penetration, the female experienced preorgasmic sensations but no real orgasm. Each session took about 15 min. In the radiological evaluation, we examined and measured the pubococcygeal line, which links the pubis and the coccyx, the axis of the penis outside and inside vagina, and the anatomical connections between the penis and the female anatomical structures.

RESULTS

In spite of the experimental conditions, the couple did not experience any difficulty having intercourse in the MRI scan. In the first session without

penetration (the female on the left and the male on the right side), the axis of the vagina is roughly parallel to the pubococcygeal line, and has a moderated anterior convexity that is parallel to the elevator ani (see Figures 3 and 4). The vagina axis is about 140° between the upper and the lower part (see Figure 5). The anterior vaginal length (to the anterior fornix) is 7.5 cm, and the posterior vaginal length (to the posterior vaginal fornix) is 11 cm. The cervix-pubis distance is 4.5 cm, and it is 2.5 cm above the pubococcygeal line. The uterus axis is about 30° compared to the horizontal line and $60\text{--}80^\circ$ relative to the main vaginal axis. It is normally anteverted (tilting forward), its length is 8 cm, and its width is 4.5 cm (see Figure 5).

In the second session (missionary position with the male on the left and the female on the right), the penis (corpus cavernosum) has a high signal in T2 weighted sequence (see Figure 6). There is a posterior shift of the uterus and a preferential contact of the penis with the anterior vaginal fornix and wall, the posterior bladder, and the urethra (which is not really visible) through Halban's fascia (see Figure 7). The complete penis takes the shape of a boomerang, and there is an angle between the root of the penis and the pendulous part of the erect penis, which has moved upward by about 110 degrees. The length of the pendulous part inside the vagina is about 13 cm; 1.5 cm remains outside, and the length of the root is 11 cm. There is an

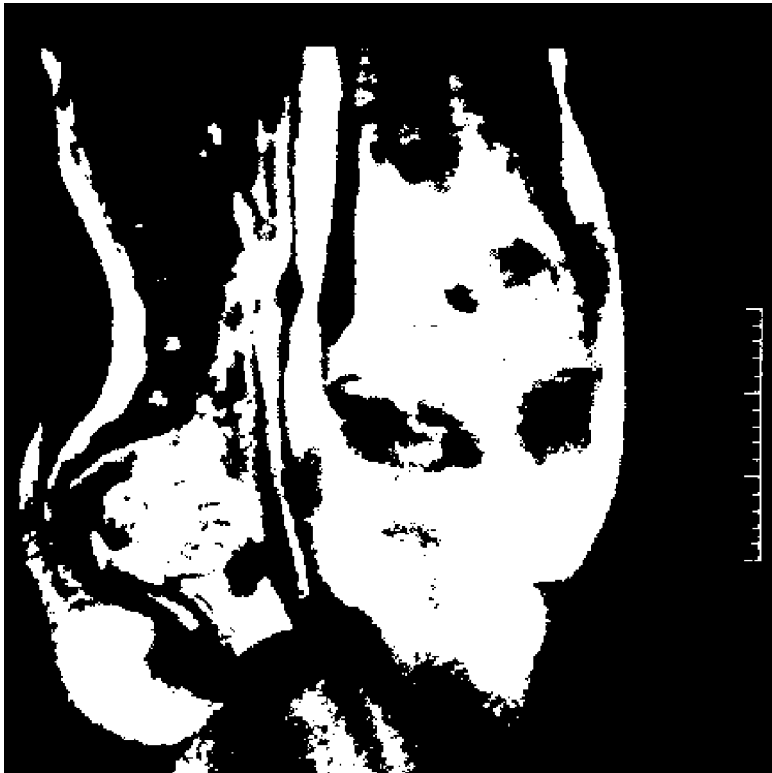

FIGURE 3. MRI first session without penetration

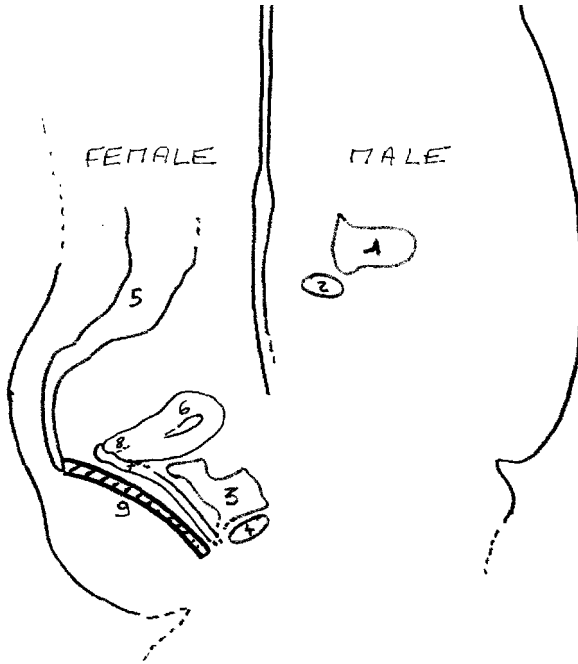


FIGURE 4. MRI first sessions diagram. (1) Male bladder; (2) Male pubis; (3) Female bladder; (4) Female pubis; (5) Sacrum; (6) Uterus; (7) Vagina; (8) Cervix; (9) Elevator ani.




FIGURE 5. MRI first session, angles and lengths; (1) Vagina axis: 140° ; (2) Uterus axis compared to the vagina axis: $60\text{--}80^\circ$; (3) Uterus axis compared to the horizontal line: 30° . Lengths: (1) uterus lengthening: 8 cm; (2) uterus width: 4.5 cm; (3) Anterior vaginal lengthening: 7.5 cm; (4) Posterior vaginal lengthening: 11 cm; (5) Cervix - Pubis: 4.5 cm, (6) Cervix - Pubococcygeal line: 2.5 cm.

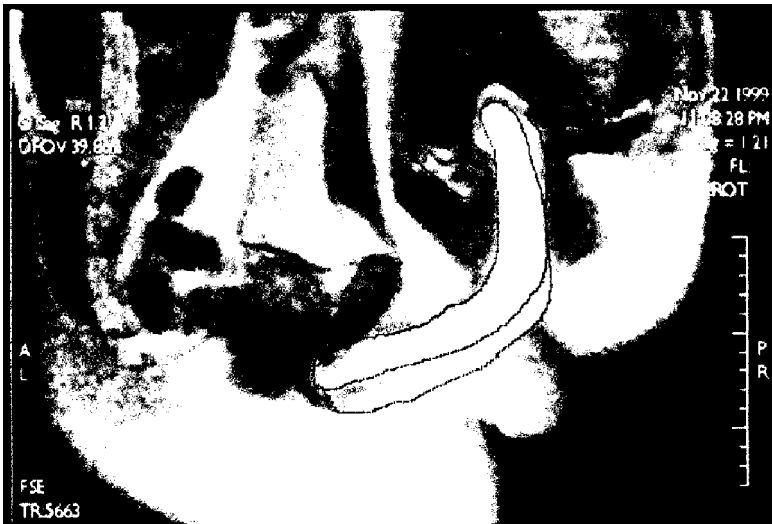

FIGURE 6. MRI second session (missionary position)

increase in the length of the vagina, which has almost doubled and become the same length as the penis. Therefore, there is a significant amount of stretching, with an increase from 7.5 cm to 13 cm (75%), and a vaginal tenting of the anterior fornix. The glans of the penis is closed to the corpus uteri and 4 cm above the cervix. The female bladder is almost empty. There is an increase of the anterior convexity of the vagina and preferential contact with the anterior fornix and the bladder, which is pushed forward and upward. The uterus is raised by 2.5 cm and there is a forward movement when

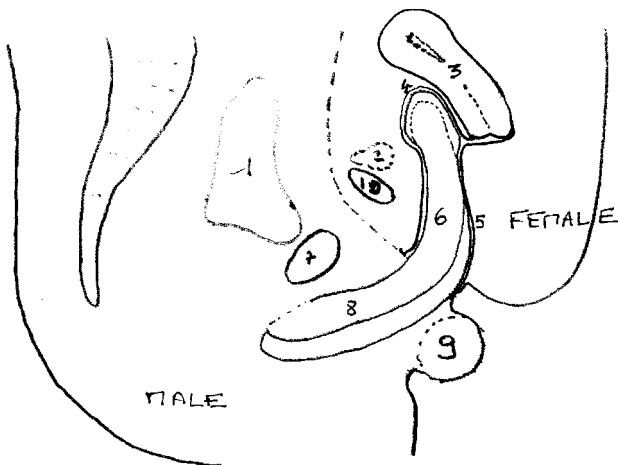


FIGURE 7. MRI second session diagram. (1) Male bladder; (2) Female bladder; (3) uterus; (4) Anterior fornix; (5) Posterior vaginal wall (6) Erect part of the penis inside vagina; (7) Male pubis; (8) Root of the penis; (9) Testis; (10) Female pubis.

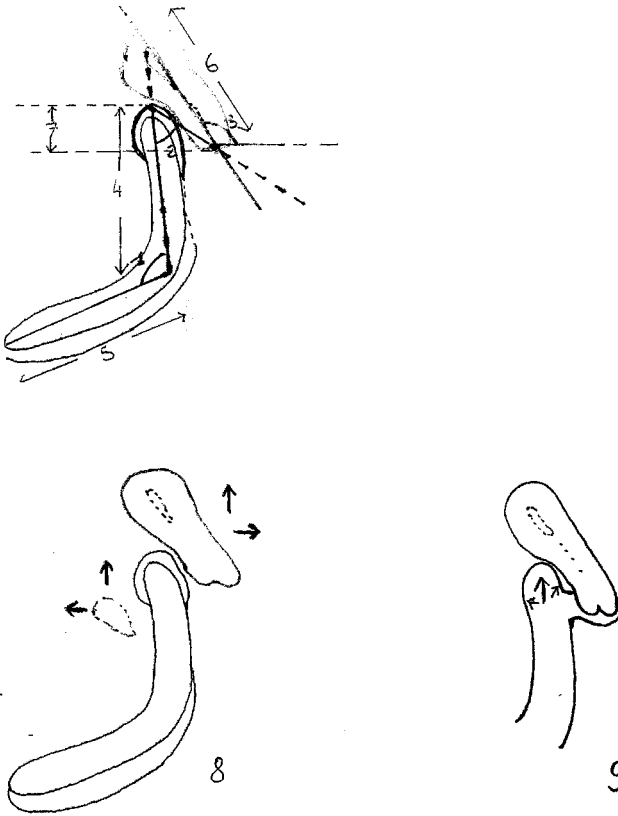


FIGURE 8. MRI second session, angles and lengths. (1) Angle 110° ; (2) Angle 50° ; (3) Angle 60° ; (4) 13 cm; (5) 11 cm; (6) 8 cm; (7) 4 cm; (8) Uterus pushed upward and backward, bladder pushed upward and forward; (9) Vaginal tenting of the anterior fornix.

compared to the pubococcygeal line. The uterus axis to the horizontal line is 60° and is turned slightly upward. Compared to the vagina axis, the uterus is at an angle of 25° (see Figure 8). The vaginal axis changes from 140° to 50° because of the anterior vaginal tenting. The size of the uterus is unchanged despite the female's preorgasmic sensations.

In the third session (rear-entry position), there is preferential contact of the penis with the posterior wall of the vagina and probably with the posterior fornix as well as the rectum through the vaginal wall (see Figures 9 and 10). The penis has roughly the same shape and the same angle (100°). The length inside the vagina is 13 cm, which is the same as in the missionary position (see Figure 11). There is no increase of the vaginal length to match the depth of penetration, but there is a vaginal tenting of the posterior fornix. The stretching of the posterior vaginal wall is less significant (11 to 13 cm, 20%). There also is a decrease of the vaginal anterior convexity, which became concave, produced by the glans reaching the posterior fornix. The corpus uteri can be seen very clearly but is not exactly sagittal; therefore, we

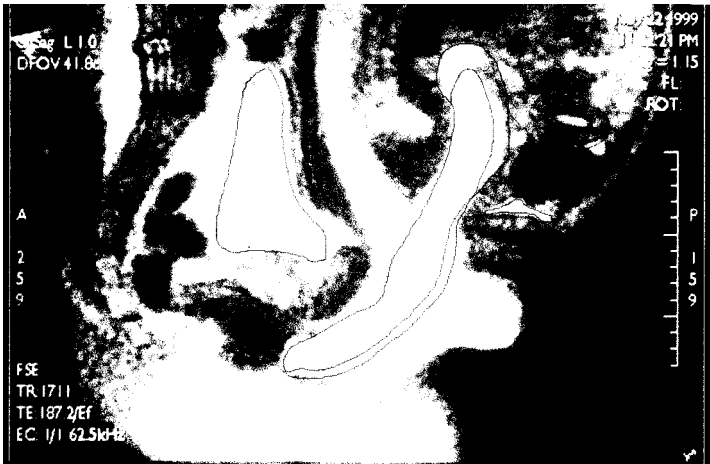

FIGURE 9. MRI third session (rear entry position)

cannot see with certitude the cervix, which seems to be situated laterally compared to the penis and corpus. But, it is possible that it may have been squashed flat at the bottom of the posterior fornix. The uterus is swung down by 4 cm from its axis, which is now almost horizontal (see Figure 11). The main problem with these images is understanding the behavior of the cervix because of the poor visibility of the fornix. However, the glans initially pushes the cervix upward and swings the uterus downward. Thereafter, it seems to reach the posterior fornix so that in the rear-entry position, the bladder and uterus were pushed forward. Compared to its shape in the missionary position, the uterus is more deformed and has a completely different axis. The changes in length and axis of the different structures are summarized in Table 1.

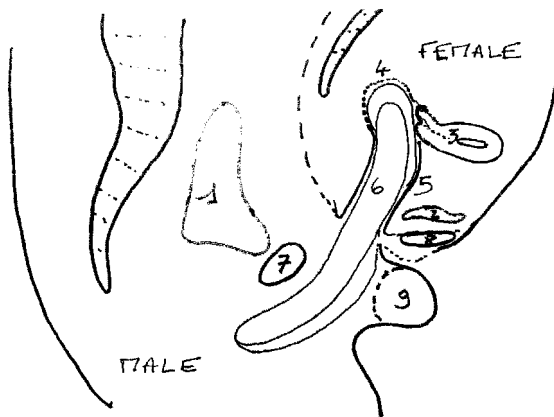


FIGURE 10. MRI third sessions diagram. (1) Male bladder; (2) Female bladder; (3) Uterus; (4) Posterior fornix; (5) Anterior vaginal wall; (6) Erect part of the penis inside vagina (7) Male pubis, (8) Female pubis; (9) Testis.

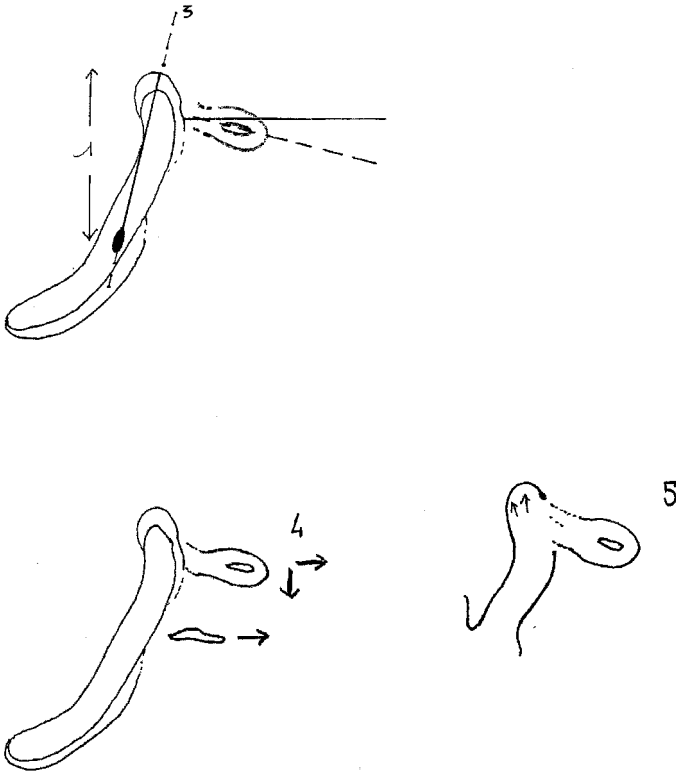


FIGURE 11. MRI third sessions, angles and lengths. (1) 13 cm; (2) 10°; (3) Penis axis = Vagina axis; (4) Uterus pushed downwards and forwards, cervix upwards?; (5) Vaginal tenting of the posterior fornix (cervix no depicted)

In the fourth and last session, again in missionary position, the sperm can be seen with a high signal T2 around the cervix a few minutes after male ejaculation (penis is still inside the vagina; Figures 12 and 13).

DISCUSSION

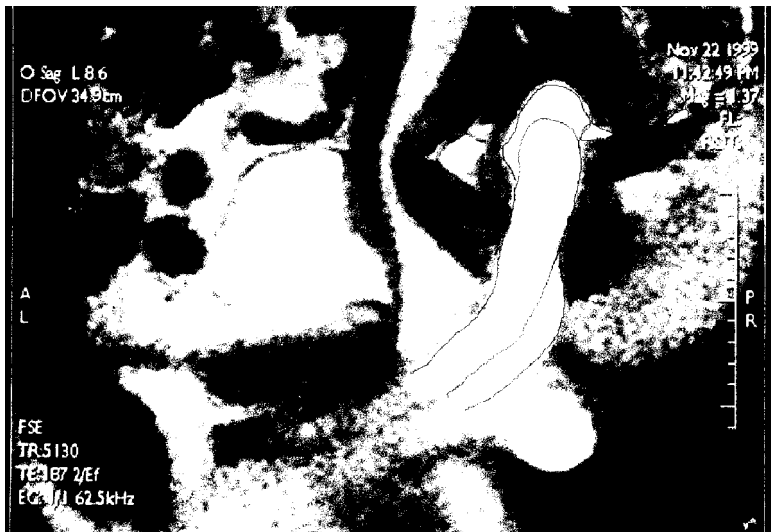The research team took 2 years to complete this study and came up against various difficulties and obstacles. But is this experience representative of the normal physiology of sexual intercourse? The couple replied that it was comparable even under the particular conditions—with preorgasmic sensations for the female in both positions and an ejaculation with orgasm for the male in the missionary position.

The hypothesized anatomy of human coitus, as drawn by Leonardo da Vinci in 1493, by Dickinson (1949), and by Zwang (1990) could be tested with MRI. According to our study, there is preferential contact with the anterior fornix in missionary position and with the posterior fornix in rear-entry

TABLE 1. Comparative Table According to the Position

	Before penetration	Missionary position	Rear-entry position
Vagina			
Axis	140°	50°	180°
Anterior vaginal length	7.5 cm	13 cm	
Posterior vaginal length	11 cm	13 cm	
Uterus			
Axis/horizontal line	30°	60°	10°
Length	8 cm	8 cm	?
Width	4.5 cm	4.5 cm	4.5 cm
Translation		Pushed up & backward	Pushed down & forward
Bladder			
	#empty	Pushed up & forward	Pushed forward
Penis			
Erect part	13 cm	13 cm	
Impact point		Anterior fornix	Cervix and posterior fornix
Shape		Boomerang	Boomerang

position. The images showed that during intercourse, whatever the position, the penis is never straight, as drawn by Leonardo da Vinci and Zwang, but takes on the shape of a boomerang and not of an S, as described by Dickinson. These three authors clearly underestimated the size of the root of the penis. The boomerang shape of the erect penis could be the explanation for the anatomical differences between the theoretical diagrams and those obtained by our MRI study. We also must note the differences with the conclusions of

**FIGURE 12.** MRI fourth session (missionary position, immediately after ejaculation).

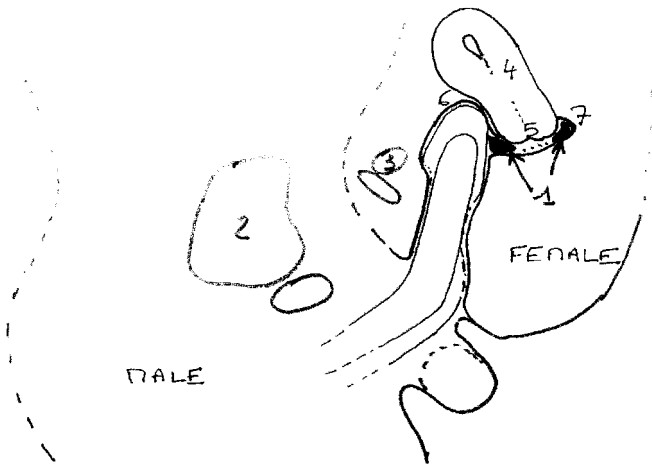


FIGURE 13. MRI fourth session diagrams (1) Sperm; (2) Male bladder; (3) Female bladder; (Uterus; (5) Cervix; (6) Anterior fornix; (7) Posterior fornix.

the ultrasound study by Riley and Riley in 1992; even in rear-entry position, there was preferential contact of the penis with the cervix for only two out of nine couples. However, self-scanning, the poor quality of the images, and the unavailability of these make correct interpretation difficult, perhaps even impossible. As for the MRI study performed by Schultz et al. (1999), in one out of four couples, the penis reaches the posterior fornix, however, the uterus seems to be retroverted, and we do not have an MRI image of the female pelvis prior to penetration.

In light of these radiological studies, must we conclude that female genital stimulation has a strong positional influence and is dependent on the coital position of the vaginal and uterus axis? We could suggest that, according to these anatomical facts, there possibly are two types of vaginal orgasms, one from preferential stimulation of the anterior vaginal wall (G-spot? Graffenberg, 1950) and one from deeper preferential stimulation of the posterior wall of the vagina and cervix (and perhaps the posterior fornix?) Histological studies (Hilleges, Falconer, Ekmon-Orderberg, & Johanson, 1995; Krantz, 1985) and immunohistochemistry have shown that the anterior wall of the vagina has denser innervation than the posterior wall. This is supported by clinical studies and research of intravaginal sensitivity to electric stimuli (Alzate & London, 1984; Hoch, 1986; Schultz, Van de Wiel, Klatter, Sturm, & Nauta, 1989). Obviously, we need to be very careful about this artificial dichotomy of the vaginal orgasm before other studies are conducted, because our study was carried out using only one couple and the deductions are hypothetical. Concerning the female internal genitals (Levin, 1998) and the changes during intercourse (thickening of the vaginal wall due to vasodilatation, lubrication, lengthening and widening of the vagina and urethra,

changes in axis, position and size of the uterus), because of the resolution of our equipment, we are only able to see the movements of the uterus and the bladder according to the coital position. We also can observe the lengthening of the vagina and its volume, which is initiated by the erect pendulous part of the penis. In contrast to the findings of Masters and Johnson (1966) and Schultz, our images did not show an increase in the size of the uterus even when the female have preorgasmic sensations.

CONCLUSION

Initially, the aim of the study was to “copy” the genius Leonardo da Vinci. We showed that an MRI scan of sexual intercourse in two positions is feasible and artistic but not as artistic as the images drawn by Da Vinci. In our study of one couple, during intercourse, the erect penis takes on the shape of the boomerang and is not straight or S shaped. Depending on the coital position, the preferential impact of the glans seems to differ, as does the behavior of the cervix and the uterus. There is, therefore, a higher probability of a difference in stimulation, thus the pleasure felt as a result may also be different. Obviously, we need to continue with further studies, which are planned in different couples. However, it is important to remember that, whatever the position, female arousal depends on various psychological aspects, which are probably different for each woman. MRI could be a new tool to assess the physiology of sexual intercourse.

REFERENCES

- Alzate H., & London, M. L. (1984). Vaginal erotic sensitivity. *Journal of Sex & Marital Therapy*, *10*, 49–56.
- Clark, K., & Pedretti, O., (1968). The drawings of Leonardo da Vinci in the collection of Her Majesty the Queen at Windsor Castle. London: Phaidon.
- Dickinson, R. L. (1949). *Human sex anatomy, A topographical band atlas* (2nd ed.). London: Braillier, Tindall, and Cox.
- Faix, A. (2001). Magnetic resonance imaging of sexual intercourse: Initial experience. *Journal of Sex and Marital Therapy*, *27*, 475–482.
- Graffenberg. (1950). The role of urethra in female orgasm. *International Journal of Sexology A current appraisal*, *3*, 145–148.
- Hilleges, M., Falconer, C., Ekmon-Orderberg. G., & Johanson, O. (1995). Innervation of the human vaginal mucosa as revealed by PG P 9.5 immunochemistry. *Acta Anatomica*, *153*, 119.
- Hoch. (1996). Vaginal erotic sensitivity by sexual examination. *Acta Obstetrics Scandinavia*, *5*, 767–773.
- Krantz , K. E. (1985). Innervation of the human vulva and vagina. *Obstetrics and Gynaecology*, *12*, 382–396.

- Levin, R. J. (1998). Sex and the human female reproductive tract :what really happens during and after coitus. *International Journal of Impotence Research*, 10 (suppl. 1), 14–21.
- Masters, W. H., & Johnson, V. E. (1966). *Human sexual response*. Boston: Little, Brown .
- Riley A. J., Lee, W., & Riley, E. J. (1992) . An ultrasound study if human coitus. In W. Bezemer, P. CohenpKettenis,K. Slob, N. Van San-Sehoonts (Eds.), *Sex matters* (pp. 29–36). Amsterdam: Elsevier.
- Schultz W. G. M., Van Andel, P., Sabelis, I., & Mooyart, E. (1999). Magnetic resonance imaging of male and female genitals during coitus and female sexual arousal. *British Medical Journal*, 319, 1596–1600.
- Schultz , W. G. M , Van de Wiel , H. B. M., Klatter, J. A., Sturm, B. E., & Nauta, J. (1989). Vaginal sensitivity to electric stimuli, Theoretical and practical implications. *Archives of Sex Behavior*, 18, 87–95.
- Zwang, G. (1990). *Abrégé de sexologie*. Paris: Edition Masson.

ALL IMAGES AND DIAGRAMS ARE UNDER COPYRIGHT IN MY NAME. I AGREE THEY CAN BE PUBLISHED PURELY FOR THE PURPOSES OF THIS ARTICLE.